

## Case Report

# PARAGANGLIOMA OF TRANSVERSE MESOCOLON: A CASE REPORT

Saira Saleem\*, Amer Sakati\*\*

\*Assistant Professor of Surgery, Madina Teaching Hospital (UMDC), Faisalabad

\*\*Chief of General Surgery, King Fahad Specialist Hospital, Buraidah, Qasseem, Saudi Arabia

## ABSTRACT

Paragangliomas are tumors of neural crest-derived cells that exist along the distribution of autonomic nervous system. Less than 10% of paragangliomas occur in extra-adrenal sites and extend anywhere from the neck to the base of the pelvis. In the abdomen these are symmetrically distributed along the abdominal aorta. Rarely, these occur aberrantly outside this distribution as in this case report. We report a case of 51 year old male with transverse mesocolon paraganglioma, presented at King Fahad Specialist Hospital, Buraidah, Saudi Arabia. It was confirmed histologically and immunohistochemically. Although rare, paraganglioma should be included in the differential diagnosis of solid mesenteric tumours, to prevent any potential life-threatening event preoperatively in the case of a catecholamines-producing tumour.

**KEY WORDS:** Transverse mesocolon paraganglioma, Extra-adrenal paraganglioma, Neuroendocrine tumour.

## INTRODUCTION:

Paragangliomas arise from chromaffin cells in the sympathetic and parasympathetic nervous system and may be found within the skull base, neck, chest, and abdomen<sup>1</sup>. The World Health Organization reserves the term pheochromocytoma for tumors arising from chromaffin cells in the adrenal medulla. Closely related tumors in extra-adrenal sympathetic and parasympathetic paraganglia are classified as extra-adrenal paragangliomas<sup>2</sup>.

In the abdomen these are symmetrically distributed along the abdominal aorta. They may mimic conditions related to specific retroperitoneal organs such as the pancreas, kidneys, or adrenals<sup>1</sup>. Rarely, these occur aberrantly outside this distribution as in this case report. Paragangliomas are classed as either functional or nonfunctional based on production of catecholamines<sup>3</sup>. Abdominal paragangliomas are mostly benign with good prognosis; however, they can present with abdominal pain, palpable mass, or hypertensive episodes. Patients should be evaluated by computed tomography or magnetic resonance imaging to locate the tumour. Surgical excision remains the mainstay of treatment<sup>1</sup>. This case

report describes a case of transverse mesocolon paraganglioma.

## CASE REPORT:

We report a case of transverse mesocolon, nonfunctional paraganglioma, which was successfully resected. A 51-year-old man presented in King Fahad Specialist Hospital, Buraidah with complaints of a mass palpable in his right upper quadrant and off and on pain in the mass. No history of jaundice, bleeding per rectum, altered bowel habits, hematemesis, melena. No history of palpitation, sweating, headache, hypertension. Blood complete and blood chemistry were within normal limits. Ultrasound abdomen showed a mixed echogenic mass mainly related to bowel. Colonoscopy was normal, no intraluminal or transmural colonic mass was found. Computed tomography showed a solid and cystic mass with good vascularity, just below liver but not

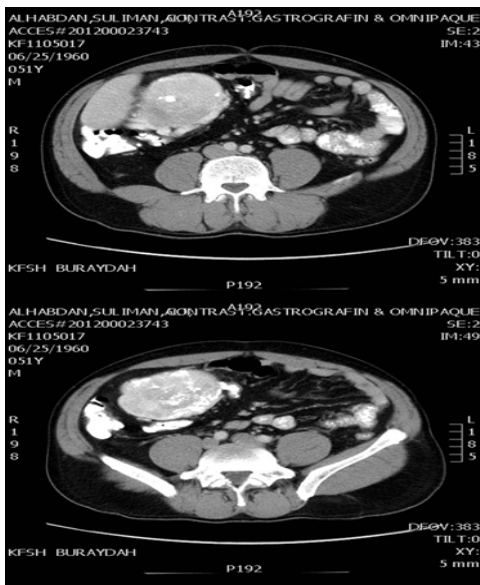
*Corresponding Author:*

Dr. Saira Saleem

Assistant Professor of Surgery Madina Teaching Hospital.

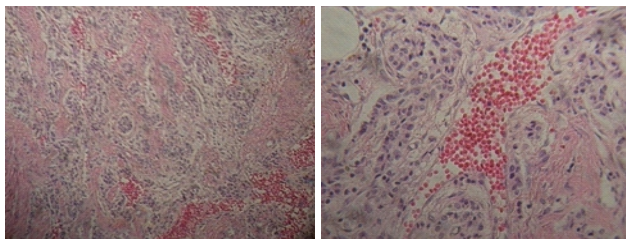
Email: dsairajaz32@yahoo.com

invading it and without any distant metastasis (Fig 1).



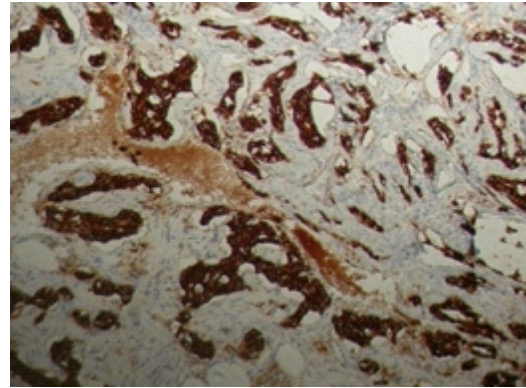
**Fig 1: Contrast enhanced CT abdomen showing a hypervascular intraperitoneal mass with enlarged surrounding vessels. Also the mass contacts but not invades the liver.**

On exploration, a well defined mass, about 7x8 cm with prominent blood vessels supplying it, was found in the transverse mesocolon. There was no pedicle and no connection of the tumor to the abdominal or retroperitoneal organs. No evidence of any metastasis (visceral or lymph nodes) was found. Complete excision of the tumor was performed. Histological findings showed oval and polyhedral cells arranged in nested (Zellabalen) pattern separated by fibrovascular septa (Fig 2).



**Fig 2: Histopathologic pic shows oval & polyhedral cells (chief cells) arranged in nests and a mixture of trabecular and alveolar pattern. These groups of cells are separated by fibrovascular septa, giving a "zellballen" (nested pattern).**

These findings were suggestive of **paraganglioma**, It was confirmed immunohistochemically. Intracytoplasmic chromaffin granules stained positive with synaptophysin and chromogranin stains (Fig 3).



**Fig 3: Chromogranin A (brown immunohistochemical stain) confirms neuroendocrine origin, supporting the diagnosis of paraganglioma.**

The postoperative period was uneventful. The patient did not receive any further treatment. Pt was referred to oncology for follow up. Nine months after surgery, investigations including CT scan did not reveal any local recurrence or distant metastasis.

#### DISCUSSION:

Paragangliomas are rare neuroendocrine tumors. They may develop anywhere from the neck to the pelvis; however, mostly they arise intra-abdominally<sup>3,4</sup>. Paraganglioma as a transverse mesocolon mass is extremely rare and only occasional reports have been published<sup>5,6</sup>.

Paraganglioma may be discovered in the absence of any symptom. When symptomatic, the clinical findings are related to the hypersecretion of catecholamines or to the compression of several anatomical structures from a growing mass. The diagnosis of the secreting forms may be obtained on the basis of biochemical dosage of serum and urinary catecholamines and metanephrines. However secreting property is only found in 25% of paragangliomas. Anatomical imaging with US/CT/MRI are equally as effective in

identifying the abdominal masses. Finally, surgical resection is the form of treatment that has achieved the best results<sup>7</sup>.

In this case ultrasonography and computed tomography showed a solid, cystic mass with increased vascularity peripherally. Exploratory laparotomy confirmed the presence of a large, solid, cystic mass in the transverse mesocolon. Histopathology showed "zellballen" pattern formed by nests of polygonal cells separated by fibrovascular septa. However literature shows that pheochromocytomas and other paragangliomas show enormous variability in cytology and histologic pattern and must be distinguished from a variety of endocrine and nonendocrine tumors. The classic "zellballen" pattern may not be evident. So a further immunohistochemical study is needed to define the tumour, for example immunohistochemical positivity for synaptophysin or chromogranin A, a major constituent of the matrix of catecholamine containing secretory granules<sup>2</sup>. In this case positive staining for synaptophysin and chromogranin A, distinguished paragangliomas from tumors that are not neuroendocrine, such as those of the adrenal cortex. Similar histological and immunohistochemical features are presented by Svajdler and colleagues for a paraganglioma of mesentery<sup>8</sup>.

The assessment of malignancy for paragangliomas is not always feasible. Several imaging, cytological and histological parameters have been proposed as predictors of malignancy, but the only element widely accepted is the existence of distant metastasis<sup>7</sup>. Current World Health Organization classification also defines malignancy of pheochromocytomas and paragangliomas by the presence of metastases not local invasion<sup>2</sup>. Although rare, paraganglioma should be included in the preoperative differential diagnosis of solid mesenteric tumours, to prevent any potential life-threatening event peroperatively in the case of a catecholamines-producing tumour<sup>7</sup>.

## CONCLUSION:

Transverse mesocolon paraganglioma are rare tumours. They can present with pain, mass or hypertensive episodes. Surgical excision

remains the mainstay of treatment. The recognition of this tumour as a cause of an abdominal mass is very important to prevent any potential life threatening event peroperatively. .

## REFERENCES:

1. Sangster G, Do D, Previgliano C, Li B, LaFrance D, Heldmann M. Primary retroperitoneal paraganglioma simulating a pancreatic mass: a case report and review of the literature. *HPB Surg* 2010.
2. Tischler AS. Pheochromocytoma and Extra-Adrenal Paraganglioma: Updates. *Arch Pathol Lab Med* 2008; 132: 1272-1284
3. Kakuta Y, Kawamura N, Fukuhara S, Imazu T, Hara T, Yamaguchi S, Adachi S Case of retroperitoneal paraganglioma. *Hinyokika Kyo. Acta Uro Jap* 2007; 53: 801-4.
4. Muzaffar S, Fatima S, Siddiqui MS, Kayani N, Pervez S, Raja AJ. Mesenteric Paraganglioma. *Can J Surg* 2002; 45: 459-60
5. Nakamura Y, Shinyama N, Higashiyama M, Kato T, Nakayama H and Okamura R. A case of paraganglioma arisen in the transverse mesocolon. *Nihon Rinsho Geka Gakkai Zasshi (J Japan Surg Assoc)* 2010; 71: 1333-1336.
6. Kim HI, Koo BK, Lee YJ, Kim JT, Cho YM, Lee KU, and Kim SY. A case of Paraganglioma Arising in the Transverse Mesocolon. *J Korean Soc Endocrinol* 2005; 20: 496-501. Published online 2005 May 20. <http://dx.org/10.3803/jks.2005.20.5.496>
7. Giangrande, Paliogiannis P, Denti S, Attene F, Scoqnamillo F, Serventi F, Targnano M. Surgical management of a voluminous abdominal paraganglioma and review of the literature. *Ann Ital Chir* 2011; 82: 211-5
8. Svajdler M, Bohus P, Zavacky A, Juskanicova E. Paraganglioma of mesentrium: A case report. *Cesk Patol* 2007; 43: 153-6.

Submitted for publication:	02.12.2015
Accepted for publication:	10.02.2016